

Successful Chemotherapeutic Management of TVT in Dogs – Report of 24 Cases

M.Saibaba*, N.Dhana Lakshmi and M.S.S.V. Phaneendra

Dept. of Surgery and Radiology
College of Veterinary Science, Tirupati

Abstract

Twenty four dogs of either sex presented with a history of abnormal mass and bleeding from vagina or prepuce. Cytological examination was carried out and diagnosed as TVT. The dogs were treated with vincristine sulphate intravenously, once a week, for four weeks. The response to chemotherapy with vicristine was excellent leading to complete regression of the neoplasm and no relapse after a year.

Keywords: dogs, TVT, vincristine

The transmissible venereal tumor (TVT) is a contagious neoplasm that occurs in sexually mature dogs, usually transmitted by coitus. The neoplasm usually affects the mucosa of the penis or vagina and less frequently the oral cavity (Sharma *et al.*,2012) and nasal passage (Gurel *et al.*, 2002). Initially the tumor is small, subsequently progressing to a large, ulcerated, and contaminated mass. The lesions are friable, hyperemic, hemorrhagic, multilobular, cauliflower like masses. TVTs are locally aggressive and rarely metastatic. This paper reports cases of TVT affecting primarily the external genitalia of dogs and its successful treatment with vincristine sulphate.

History and Clinical Observations

Dogs between the age group of 5 – 10 years, among those males (8) and bitches (16) were presented to the Dept. of Surgery & Radiology with a history of bleeding from vagina or prepuce (Table 1). Clinical examination revealed large pedunculated cauliflower like

growths at vagina (Fig.1) and prepuce (Fig.2), which were firm in consistency. Diagnosis was made by cytological examination of localized tissue by FNAC as non- aspiration technique and impression smear of soft tissue. Cytological examination revealed uniform round cells containing light colored cytoplasm with multiple vacuoles and large nucleus and a prominent, central located nucleolus (Fig.3). These findings were consistent with the diagnosis of TVT.

Table.1 Incidence of TVT in different breeds

S.No	Breed	Male	Female
1	Mongrel	4	7
2	Pomerarian	2	4
3	Labrador	1	2
4	German shepherd	1	2
5	Daschund	0	1
Total		8	16

Treatment and Discussion

The animals were treated weakly receiving vincristine sulphate (Oncocristine) at a dose rate of 0.65 mg/m² intravenously through normal saline for four weeks. Significant remission of the lesion was noticed before the second vincristine injection (Fig.4). Complete remission of the TVT was observed four weeks after initial treatment. (Fig.5). Periodic evaluations every 3 months were carried out and there were no signs of recurrence after one year. All animals showed uneventful recovery. Medical treatment of TVT is well established and usually successful (Rogers *et al.*,1998).

Transmissible veneral tumor mostly develops in the genital organs of both sexes and is generally considered as a benign tumor. The incidence of metastasis is quite low and occurs in 5 % or less of the cases (Sharma *et al.*,2012). It was also transmitted by social

behaviour which may help to explain cases of extra genital TVT in nasal and oral cavities. The most common site of metastasis was the regional lymphnode (Bastan *et al.*, 2008). Definitive diagnosis is based on physical examination and cytological findings, which are obtained through swabs, fine needle aspirations or imprints of the tumor (Kroger *et al.*, 1991). In the present report, the diagnosis was based on clinical signs and was confirmed by cytological examination, carried out through fine needle aspiration.. Several treatments including surgery, radiotherapy, immunotherapy, biotherapy, and chemotherapy have been reported for TVT (Pigatto *et al.*, 2011). Normally, the intravenous administration of vincristine at the dose of 0.6 mg/m² to 0.8mg/m² of body surface, once a week, for 2-6 weeks, is the treatment of choice regardless of the neoplasm size, extent, and duration of the disease (Tella *et al.*, 2004). In the present report, the four-week regimen of intravenous administration of vincristine sulphate at 0.65mg/m² body weight, alone, was very effective for complete remission of the tumor. Its regression was clinically evident within the first week of treatment. A complete remission usually takes 2 to 8 injections (Tella *et al.*, 2004), and, in the present case, occurred in 21 days, being followed by another week of treatment. No recurrence has been observed after a year. In case of failure, radiotherapy provides excellent results; alternatively, doxorubicin chemotherapy may be applied (Pigatto *et al.*, 2011). Side effects following administration of vincristine such as myelosuppression, gastrointestinal effects, and paresis, due to peripheral neuropathy, have been correlated with and may occur in 5 to 7% of the patients (Tella *et al.*, 2004). The occurrence of local tissue reactions caused by extravasation of the drug during IV administration is a common complication (Pigatto *et al.*, 2011).

Summary

Successful chemotherapeutic management of TVT with Vincristine sulphate in dogs have been reported and discussed.

References

- Bastan, A., Baki Acar, D. And Cengiz, M. (2008) Uterine and ovarian metastasis of transmissible venereal tumor in a bitch. *Turk.J.Vet.Anim. Sci.*, **36**:65
- Gurel, A., Kuscu, B., Gulanber, E.G. and Arun, S.S. (2002) Transmissible Venereal Tumors Detected in the Extragenital organs of Dogs. *Israel J. Vet. Med.* **57** (2):1
- Kroger, D., Grey, R.M. and Boyd, J. W. (1991) An unusual presentation of canine transmissible venereal tumor. *Canine Practice*, Santa Barbara, **16**(6):17-21
- Pigatto, J.A., Hunning, P.S., Bercht, B.S. and Albuquerque, L. (2011) Transmissible venereal tumor in the palpebral conjunctiva of a dog: case report. *Semina: Agricultural Sciences* **32**(3):1139-1144
- Sharma, A.K., Kumar, H., Kumar, S. And Kiran, D. (2012) *Indian Vet. J.* **89**(11):78-79
- Tella, M. A., Ajala, O. O. and Taiwo, V. O. Complete regression of transmissible venereal tumour (tvt) in nigerian mongrel dogs with vincristine sulphate chemotherapy. *African Journal of Biomedical Research*, Ibadan, v. 7, n. 3, p. 133-138, 2004.

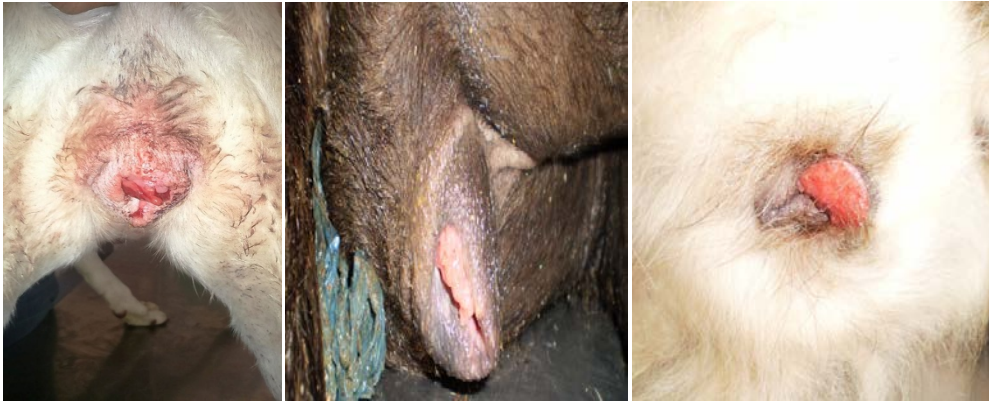

Fig. 1 Pedunculated growths at Vagina

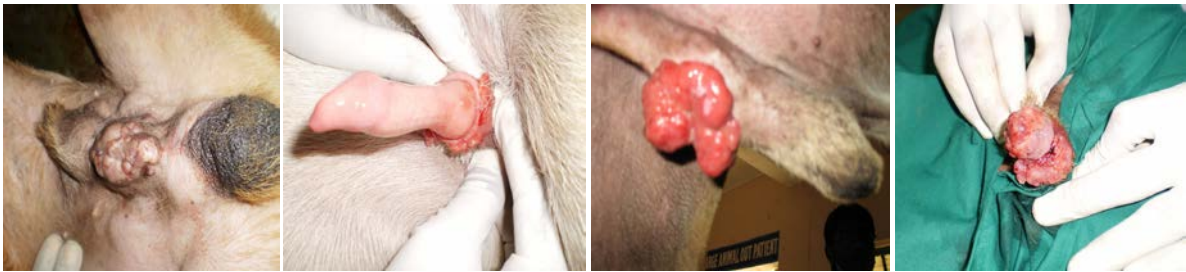


Fig.2 Cauliflower like growths at prepuce

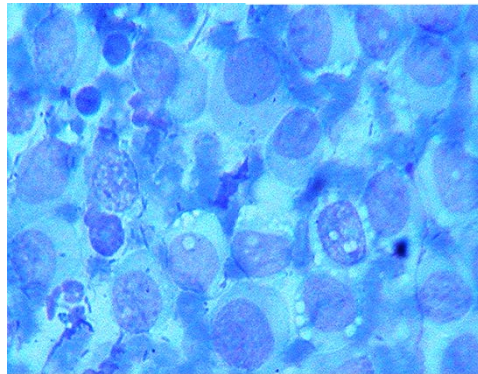


Fig.3 Photograph showing uniform population of round cells

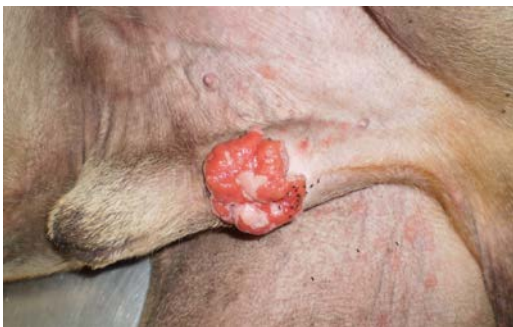

Fig.4 Significant remission of the lesion

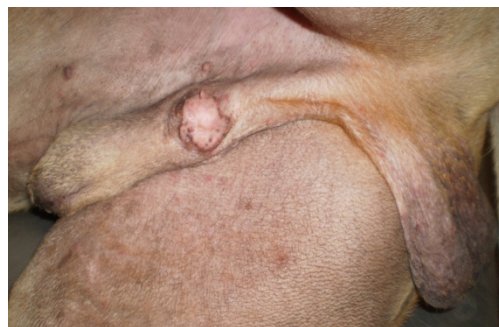

Fig. 5 Complete remission